

DIAGNOSIS AND MANAGEMENT

Testicular cancer

- Testicular cancer is the most common cancer in men aged 20-40 years, and accounts for approximately 1-1.5% of all cancers in men
- The majority of tumours are derived from germ cells (seminoma and non-seminoma germ cell testicular cancer)
- More than 70% of patients are diagnosed with stage I disease (pT1)
- Testicular tumours show excellent cure rates of >95%, mainly due to their extreme chemo- and radio-sensitivity
- A multidisciplinary approach offers acceptable survival rates for metastatic disease

The GP's role

GPs are typically the first point of contact for men who have noticed a testicular lump, swelling or pain. The GP's primary role is assessment, referral and follow-up. Note:

- All suspected cases must be thoroughly investigated and referred to a Urologist
- Treatment frequently requires multidisciplinary therapy that may include the GP
- Most patients will survive, hence the importance of long-term regular follow-up

- ▶ **Note on screening:** there is little evidence to support routine screening. However, GPs may screen men at higher risk, including those with a history of previous testicular cancer, undescended testes, infertility or a family history of testicular cancer.

Benign cysts

Epididymal cysts, Spermatocele, Hydatid of Morgagni and Hydrocele are all non-cancerous lumps that can be found in the scrotum. Diagnosis can be confirmed via an ultrasound.

EPIDIDYMAL CYSTS

Common fluid-filled cysts which feel slightly separate from the testis and are often detected when pea-sized. Should be left alone when small, but can be surgically removed if they become symptomatic.

SPERMATOCELE

Fluid-filled cysts containing sperm and sperm-like cells. These cysts are similar to epididymal cysts except they are typically connected to the testis.

HYDATID OF MORGAGNI

Small common cysts located at the top of the testis. They are moveable and can cause pain if they twist. These cysts should be left alone unless causing pain.

HYDROCELE

A hydrocele is a swelling in the scrotum caused by a buildup of fluid around the testes. Hydroceles are usually painless but gradually increase in size and can become very large. Hydroceles in younger men may be a warning of an underlying testis cancer, albeit rarely. In older men, hydroceles are a non-dangerous condition.

Diagnosis and Management

Medical history

- ❑ Trauma to the area
- ❑ Lumps/swelling
- ❑ Pain: gradual or sudden, level of pain
- ❑ Sexually active
- ❑ Dysuria
- ❑ Any other symptoms e.g. metastatic disease (cough, reduced appetite, weight loss)
- ❑ Fertility an issue

Physical examination

- Perform a clinical examination of the testes and general examination to rule out enlarged nodes or abdominal masses

▶ Clinical notes:

On clinical examination it can be difficult to distinguish between testicular and epididymal cysts. Lumps in the epididymis are rarely cancer. Lumps in the testis are nearly always cancer.

↓ Refer to GP Summary Guide 1

Ultrasound

- Organise ultrasound of the scrotum to confirm testicular mass (urgent, organise within 1-2 days)
 - always perform in young men with retroperitoneal mass

Investigation and specialist referral

- Advice on next steps for investigation and treatment
- Referral to urologist (seen within 2 wks)
- CT scan of chest, abdomen and pelvis
- Serum tumour markers (α FP, β hCG, LDH) before orchidectomy: may be ordered by GP prior to urologist consultation
- Brief advice on fertility issues
- Fine needle aspiration: scrotal biopsy or aspiration of testis tumour is **not** appropriate or advised

▶ Clinical notes:

The Urologist will form a diagnosis based on inguinal exploration, orchidectomy and *en bloc* removal of testis, tunica albuginea, and spermatic cord. Organ-sparing surgery can be attempted in special cases (bilateral tumour or solitary testes) in centres of reference.

Follow-up

- Patient follow-up (in consultation with treating specialist) for:
- Recurrence
 - Monitoring the contra lateral testis by physical examination
 - Management of complications, including fertility

Classification and risk factors

There are three categories of testicular epithelial cancer (**Box 1**). Germ cell tumours account for 90-95% of cases of testicular cancer according to the World Health Organisation (WHO) classification system. Risk factors (**Box 2**) are well established.

1. The recommended pathological classification (modified WHO, 2004)

1. Germ cell tumours

a. Seminoma

b. Non-seminoma (NSGCT)

- Embryonic
- Yolk sac
- Choriocarcinoma
- Mature teratoma

2. Sex cord stromal tumours

3. Mixed germ cell/sex cord stromal tumours

2. Prognostic risk factors

Pathological (pT1-pT4)

- Histopathological type
- For seminoma
 - Tumour size (>4cm)
 - Invasion of the rete testis
- For non-seminoma
 - Vascular/lymphatic invasion or peri-tumoural invasion
 - Percentage embryonal carcinoma >50%
 - Proliferation rate (MIB-1) >70%

Clinical (for metastatic disease)

- Primary location
- Elevation of tumour marker levels (α FP, β hCG, LDH)
- Presence of non-pulmonary visceral metastasis*

*Only clinical predictive factor for metastatic disease in seminoma.

Staging of testicular tumours

- The 2002 TNM (Tumour, Node, Metastasis) system is recommended for classification and staging purposes. The IGCCCG staging system is recommended for metastatic disease.
↓ Refer to GP Summary Guide 6.1 Supplement

Treatment of testicular cancer

- The first stage of treatment is usually an orchidectomy: removal of the diseased testicle via an incision in the groin, performed under general anaesthetic
- Further treatment depends on the pathological diagnosis (seminoma vs non-seminoma and the stage of disease) and may include radiotherapy, chemotherapy or active surveillance
 - Men with early stage seminoma are treated with radiotherapy to the ipsilateral lymph nodes
 - Men with early stage non-seminoma usually undergo close surveillance (tumour markers, chest x-ray and CT scans)
 - Men with early stage disease who relapse and men with advanced disease are generally referred for chemotherapy. If chemotherapy leaves residual masses, these may contain cancer and usually will need surgical removal
- If a man has a bilateral orchidectomy (rare) he will require ongoing testosterone replacement therapy. Some men choose to have a testicular implant during or after treatment for cosmetic reasons

↓ Refer to GP Summary Guide 6.1 Supplement

Patient support

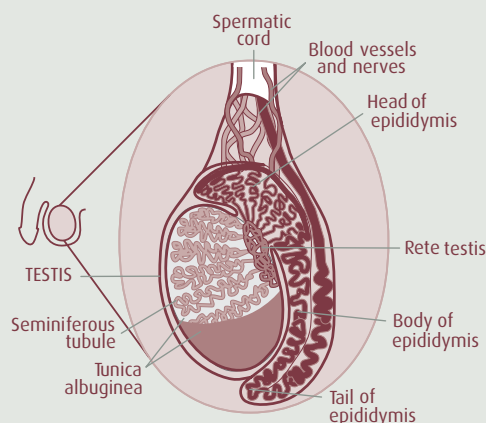
Diagnosis and treatment can be extremely traumatic for the patient and family. Regular GP consultations can offer patients a familiar and constant person with whom to discuss concerns (e.g. about treatment, cancer recurrence, and the effects of testis removal on sexual relationships and fertility). Referral to a psychologist may be required.

Patient follow-up

- **Regular follow-up is vital**, and patients with testicular cancer should be watched closely for several years. The aim is to detect relapse as early as possible, to avoid unnecessary treatment and to detect asynchronous tumour in the contra lateral testis (incidence 5%)
- **Plan follow-ups in conjunction with the specialist**. Follow-up schedules are tailored to initial staging and treatment, and can involve regular physical examination, tumour markers and scans to detect recurrence. The timing and type of follow-ups need to be determined for each patient in conjunction with the treating specialist(s)

Semen Storage

- **Radiotherapy and chemotherapy can lower sperm counts** temporarily or permanently. Men with testicular cancer often have lower fertility before treatment, and there is the risk of treatment reducing fertility further. Surgical removal of one testis does not affect the sperm-producing ability of the remaining testis
- **Provide prompt fertility advice** to all men considering chemotherapy or radiotherapy, to avoid delaying treatment. It is highly recommended that men produce semen samples for sperm storage prior to treatment. Semen can be frozen and stored long-term for future use in fertility treatments. Men who have poor sperm counts may need to visit the sperm-banking unit on 2-3 separate occasions
- **Sperm storage for teenagers can be a difficult issue** requiring careful and delicate handling. Coping with the diagnosis of cancer at a young age and the subsequent body image problems following surgery can be extremely difficult. Fatherhood is therefore not likely to be a priority concern. Producing a semen sample by masturbation can also be stressful for young men in these circumstances
- **Refer the patient to a fertility specialist** or a local infertility clinic. These clinics usually offer long-term sperm storage facilities



SCHEMATIC DIAGRAM OF THE TESTIS

Diagram courtesy Of Dr C Borg, Monash Institute Of Medical Research