

# MALE GENITAL EXAMINATION STEP-BY-STEP

# 1

EXAMINATION OF MALE GENITALS AND SECONDARY SEXUAL CHARACTERISTICS

GP SUMMARY GUIDE

## Testicular volume

Testicular volume is assessed using an **orchidometer**; a sequential series of beads ranging from 1 to 35mls (see Image 1). Testicular volume is measured using the following steps:

1. Conduct the examination in a warm environment, with the patient lying on his back
2. Gently isolate the testis and distinguish it from the epididymis. Then stretch the scrotal skin, without compressing the testis
3. Use your orchidometer to make a manual side-by-side comparison between the testis and beads (see Image 2)
4. Identify the bead most similar in size to the testis. This indicates testis volume

## Normal testicular volume ranges

CHILDHOOD:	PUBERTY:	ADULTHOOD:
< 3mls	4-14mls	15-35mls

### Clinical notes:

- Asymmetry between testes is common (e.g. 15mls vs. 20mls) and not medically significant
- Asymmetry is sometimes more marked following unilateral testicular damage
- Testes are roughly proportional to body size
- Reduced testicular volume suggests impaired spermatogenesis
- Small, firm testes (<4mls) from mid puberty are a consistent feature of Klinefelter's syndrome

## Examination of secondary sexual characteristics

### Gynaecomastia

- Gynaecomastia is the excessive and persistent development of benign glandular tissue evenly distributed in a sub-areolar position of one or both breasts (see Image 3)
- Can cause soreness and considerable embarrassment
- Common during puberty, usually resolves in later adolescence
- Causes include marijuana, androgen abuse, abnormal liver function
- Distinguish glandular tissue from sub-areolar fat in obese subjects
- Rare secondary causes include hypothalamic pituitary lesions and adrenal/testis lesions (estrogen excess)
- Rapidly developing gynaecomastia may indicate testicular tumour
- In contrast to gynaecomastia, breast cancer can be located anywhere within the breast tissue and feels firm or hard

### Onset of puberty

- Average onset is 12-13 years

### Virilisation

- Facial and body hair development
- Muscle development
- Penile growth

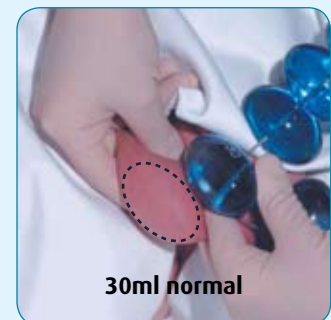


IMAGE 1 – ORCHIDOMETER

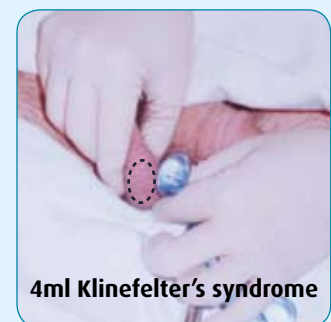## Why use an orchidometer?

Testicular volume is important in the diagnosis of androgen deficiency, infertility and Klinefelter's syndrome.

Andrology Australia acknowledges the financial support of Bayer Schering Pharma for the production of the orchidometer



30ml normal



4ml Klinefelter's syndrome

IMAGE 2 – EXAMPLE OF 30ML AND 4ML ADULT TESTIS

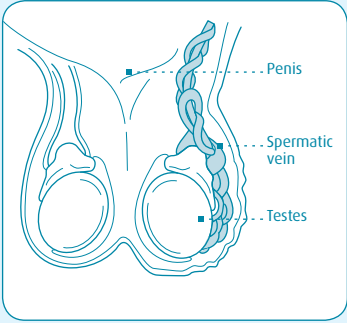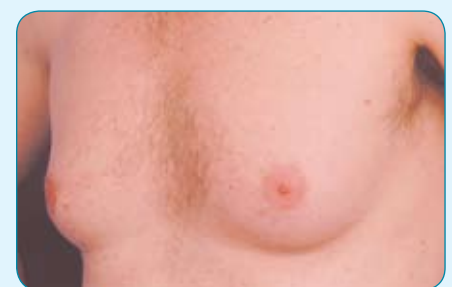



IMAGE 3 – GYNAECOMASTIA

(Photo courtesy of Mr G.Southwick, Melbourne Institute of Plastic Surgery)

# EXAMINATION OF TESTIS AND SCROTAL CONTENTS

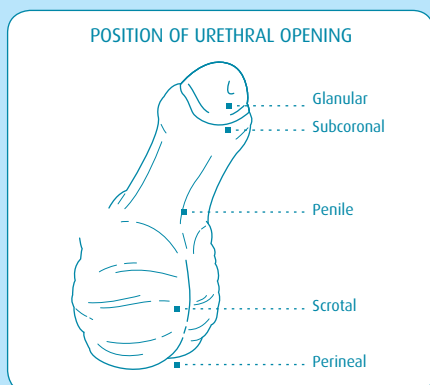
For other guides in this series visit [www.andrologyaustralia.org](http://www.andrologyaustralia.org)

TESTIS	Gently palpate the testis between your thumb and first two fingers.	If a testis cannot be felt, gently palpate the inguinal canal to see if testis can be 'milked' down.	Examine the testis surface for irregularities. It should be smooth, with a firm, soft rubbery consistency.
	Atrophic testes are often more tender to palpation than normal testes.	Testis retraction can be caused by cold room temperature, anxiety and cremasteric reflex.	A tumour may be indicated by deep or surface irregularity, or differences in consistency between testes.
EPIDIDYMIS	Locate the epididymis, which lies along the posterior wall of the testis. It should be soft, slightly irregular and non-tender to touch.	<ul style="list-style-type: none"> <li>• Tenderness, enlargement or hardening can occur as a result of obstruction (vasectomy) or infection. This can be associated with obstructive infertility.</li> <li>• Cysts in the epididymis are quite common. These are sometimes mistaken for a testicular tumour.</li> </ul>	
VAS DEFERENS	Locate the vas deferens, a firm rubbery tube approximately 2-3mm in diameter.	Nodules/thickening around the vas deferens ends may be apparent after vasectomy.	
	The vas deferens should be distinguished from the blood vessels and nerves of the spermatic cord.	Absence of the vas deferens is a congenital condition associated with low semen volume and azoospermia.	
VARICOCELE	Perform examination with the man standing. A Valsalva manoeuvre or coughing helps delineate smaller varicoceles.	<p><b>Indicators include:</b></p> <ul style="list-style-type: none"> <li>• Palpable swelling of the spermatic veins above testis</li> <li>• Swelling is usually easy to feel and can be compressed without discomfort</li> <li>• Nearly always on left side</li> <li>• Associated with infertility</li> </ul>	  <p>(Photo courtesy of Prof. D. de Kretser)</p>

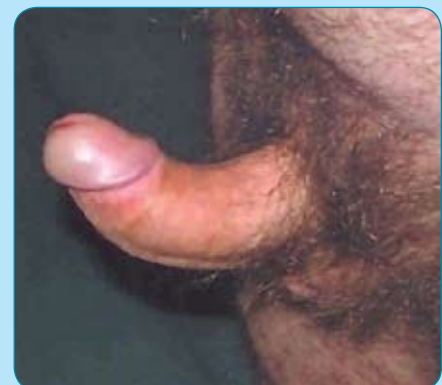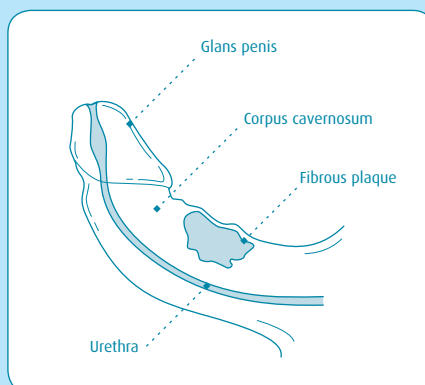
## Examination of penile abnormalities

Hypospadias	Peyronie's disease	Micropenis	Phimosis	Urethral stricture
Abnormal position of meatus on the underside of the penile shaft. May be associated with a notched penile head.	Fibrous tissue, causing pain and curvature of the erect penis. Check for tenderness or thickening.	May indicate androgen deficiency prior to puberty.	The foreskin cannot be pulled back behind the glans penis. Can be normal in boys up to 5-6 years.	Abnormal urethral narrowing, which alters urination. Can be caused by scar tissue, disease or injury.

### HYOSPADIAS



### PEYRONIE'S DISEASE



(Photo courtesy of Dr M Lowy, Sydney Centre for Men's Health)